

Mycetoma: An Overview

Revati A.Khairnar, Tejashri R.Dugaje, Ritesh A.Khairnar

SMES's mahavir institute of pharmacy,nashik,

SMES's mahavir institute of pharmacy,nashik,

St.john institute of pharmacy and research palghar.

Submitted: 15-08-2023

Accepted: 25-08-2023

ABSTRACT: Mycetoma is a chronic, catastrophic infection of the subcutaneous tissue. In that pus, blood, and fungus grains are drained from the sinuses. It's composed of 60% bacteria and 40% fungi. It is classified etiologically as either actinomycetoma, which is brought on by bacteria, or eumycetoma, which is brought on by fungus. The clinical presentation and etiological agent in the tissue as determined by mycological/bacteriological, histological, and immunohistochemical testing serve as the basis for the diagnosis. The etiology must be identified in order to determine the appropriate treatment, which might be either bacterial or fungal. The foundation for treating these conditions entails early identification, systemic administration of antibiotics or antifungal medicines, as well as surgical removal of lesions. The most frequently employed diagnostic procedures and therapeutic measures will be covered in this overview.

KEYWORDS: Actinomycetoma, eumycetoma, madurella foot, madurella mycetomatis

I. INTRODUCTION

Mycetoma is a chronic, catastrophic infection of the subcutaneous tissue (1, 2). *Madurella mycetomatis* is a common disease of Mycetoma. It mostly spreads disease to South America, Africa, and India. *Madurella mycetomatis* is the primary cause of mycetoma. Typically, pus, blood, and fungus grains are drained from the sinuses. In isolated rural areas, it usually affects teenagers and kids. Those who work in the fields or in the herb industry and come into contact with the soil most frequently are affected. Hence, the foot is the most frequently infected area (3, 4). The left foot is slightly more frequently damaged than the right, and the majority of lesions are found on the dorsal part of the forefoot. The

second most frequent place is the hand, with the right hand being more impacted (5).

Mycetoma can be brought on by a variety of microorganisms, including fungus and bacteria (*actinomycetoma* and *eumycetoma*, respectively) (6, 7, 8) refer to Table no. 1 (26-35). It's composed of 60% bacteria and 40% fungi. Across the world, the fungus *Madurella mycetomatis* is the most frequent cause of disease (9, 10, 11). Combined bacterial and fungal infections are possible, but they are quite uncommon. Since *Madurella mycetomatis* is weakly proteolytic and amylolytic, it can absorb glucose, galactose, lactose, and maltose but not sucrose. The presence of grains within the tissue is a distinguishing trait of mycetoma. As microbes infect the human body, they generate these grains, perhaps as a protection against the human immune system. It can be caused by a wide range of organisms, and different forms of grains can occur. These grains can have a variety of colors, sizes, and textures (1, 12, 13).

Madurella mycetomatis, *Trematosphaeria grisea*, *Exophiala jeanselmei*, and *Curvularia* are geniculate are all black grains of eumycetoma. The most prevalent pathogen *M. mycetomatis* has grains brown or black, 0.5-1.0 μm in size, round or lobed, stiff and brittle, and made of hyphae that are 2-5 μm in diameter, and terminal cells that have been enlarged to 12-15 μm in diameter. At 37°C, colony growth is quicker than at 25 or 30°C, and growth continues up to 40°C (14, 15, 16). Colonies start out being white before changing over time to yellow, brown, or olivaceous; they can also create a brown diffusible pigment. This brown color indicates the presence of melanin. It can be produced through various biochemical pathways. A precursor to the extracellular protein melanin, 1,8-dihydroxy naphthalene is produced by *Madurella mycetomatis*. Both molecules are responsible for the distinctive dark color of the grain (17).

The chemical content of these grains is unknown, but lipids, proteins, DHN-melanin, Cu,

Zn, and Ca are known to be present in the grain(23, 24, 25). Due to their close proximity to the host, these elements may have a significant impact on the fungal pathogenicity as well as the development of antifungal agent resistance. In general, it is understood that fungal melanins have significant protective roles for the fungus against UV light when it is in the soil and against host immune responses and antifungal medications when it is in the host. A massive granuloma formation with a sizable neutrophil zone surrounds the grain (18, 19, 20, 21, 22).

Although conidiation (conidium), an asexual reproduction method, is infrequent in *M. mycetomatis*, two primary forms may be distinguished in-vitro. Conidia of the first type range in size from 3 to 5 µm and are oval to

pyriform. On the tips of simple or branched conidiophores, the conidia have truncated bases. In-vitro, 50% of cultures on soil extract, hay infusion, or water agar show this form of conidiation. The second type of conidiation is seen when cultured on cornmeal agar or potato carrot agar.

Mycetoma infection progresses slowly and steadily. The mycetoma lesion may eventually spread to deeper tissues and bones, resulting in deformity of the afflicted spot and impairment for the patient. Mycetoma infection does not heal on its own and, if left untreated, causes enormous lesions that demand surgical amputation. And the condition is very debilitating, particularly due to lesions that develop in the limbs. The sickness has serious socioeconomic effects (26,1, 2).

Table no.1 Difference Between Eumycetoma and Actinomycetoma (26-35)

Sr.no	Eumycetoma	Actinomycetoma
1.	Eumycetoma, also known as fungal mycetoma,	Actinomycetoma, also known as bacterial mycetoma
2.	It is a chronic infection caused by various fungi, most commonly <i>Madurella mycetomatis</i> , i	is a chronic infection caused by bacteria, most commonly <i>Actinomyces</i> species.
3.	Available in tropical and subtropical regions	Available in rural areas of developing countries
4.	It typically presents as a painless, slow-growing subcutaneous mass, usually in the foot, that can spread to the bone and joints over time.	It typically presents as a painless, firm swelling, usually in the lower extremities, with draining sinuses that discharge small, yellow or white grains, which are aggregates of bacterial filaments.
5.	Diagnosis is made by identifying the characteristic grains in the discharge or biopsy samples.	Diagnosis is made by identifying the bacteria in discharge or biopsy samples.
6.	Treatment involves a long-term course of antifungal medications and surgical removal of the affected tissue.	Treatment involves a long-term course of antibiotics and surgical removal of the affected tissue.

EPIDEMIOLOGY

The most prevalent form of eumycetoma in Africa is black grain, which is mostly brought on by *Madurella mycetomatis*. Despite being widespread, mycetoma is indigenous to tropical and subtropical regions, particularly in the "mycetoma belt," or the region between latitudes 15° south and 30° north (36).

Actinomycetoma and eumycetoma incidence vary from country to country and from region to region on a worldwide scale. While eumycetoma is more common in humid locations, actinomycetoma is more common in dry areas.

In South and Central America, actinomycetes (bacterial agents) are more frequent than eumycetomas (fungal agents), which are more prevalent in Africa. The world's mycetoma epidemiology is thought to be most prevalent in Sudan. More than 7000 mycetoma patients have received treatment in Khartoum, the capital of Sudan, and the fungus *Madurella mycetomatis* has been identified as the primary culprit in 70% of those cases. Actinomycetoma are more common in Mexico and Brazil, and the primary causative agent is *Nocardia brasiliensis*(37, 38).

Some of the disease-causing microbes are located in the soil and can enter the body by a stone cut, thorn prick, or wood splinter. Mycetomas are regarded as occupational illnesses that affect people who work in rural settings, such as farmers and shepherds, or who are involved in environmental activities. Although mycetomas may affect people of any age, young males between the ages of 20 and 40 are more frequently affected. As the male-to-female ratio ranges from 3:1 to 5:1, men are more likely than women to be harmed (39, 40).

CLINICAL PRESENTATION

Initial symptoms of mycetoma include a slowly growing, mild subcutaneous swell, which occasionally coexists with a history of prior trauma. Even so, it is unclear how long it takes for the initial symptoms to manifest before the characteristic indicators appear; they might take months or even years. Investigations are made more difficult by the fact that most patients arrive late, don't exhibit any clinical symptoms, can't even access health services, or are afraid of having their limbs amputated (41, 42, 43, 44).

Mycetoma's clinical appearance might vary depending on the severity of the condition, the kind of pathogenic organism, the infection location, and even the host's immunological response. Those with a recent illness history, however, may exhibit large lesions and significant deep tissue and bone loss. Others may exhibit modest localized infections that have been present for some years without showing any signs of significant ongoing tissue deterioration. The subcutaneous swelling might be smooth and lobular or generally solid and spherical.

Usually cystic, it is frequently migrating. The size of the subcutaneous nodules grows, and additional nodules may form as well. During the active phase of the illness, the sinuses that the nodules may drain via may suppurate and temporarily shut following discharge. Even though certain older sinuses might totally heal, new sinuses next to them might emerge. Depth-sterilized abscesses as well as the skin's layer link the nodules to one another. Lesions from

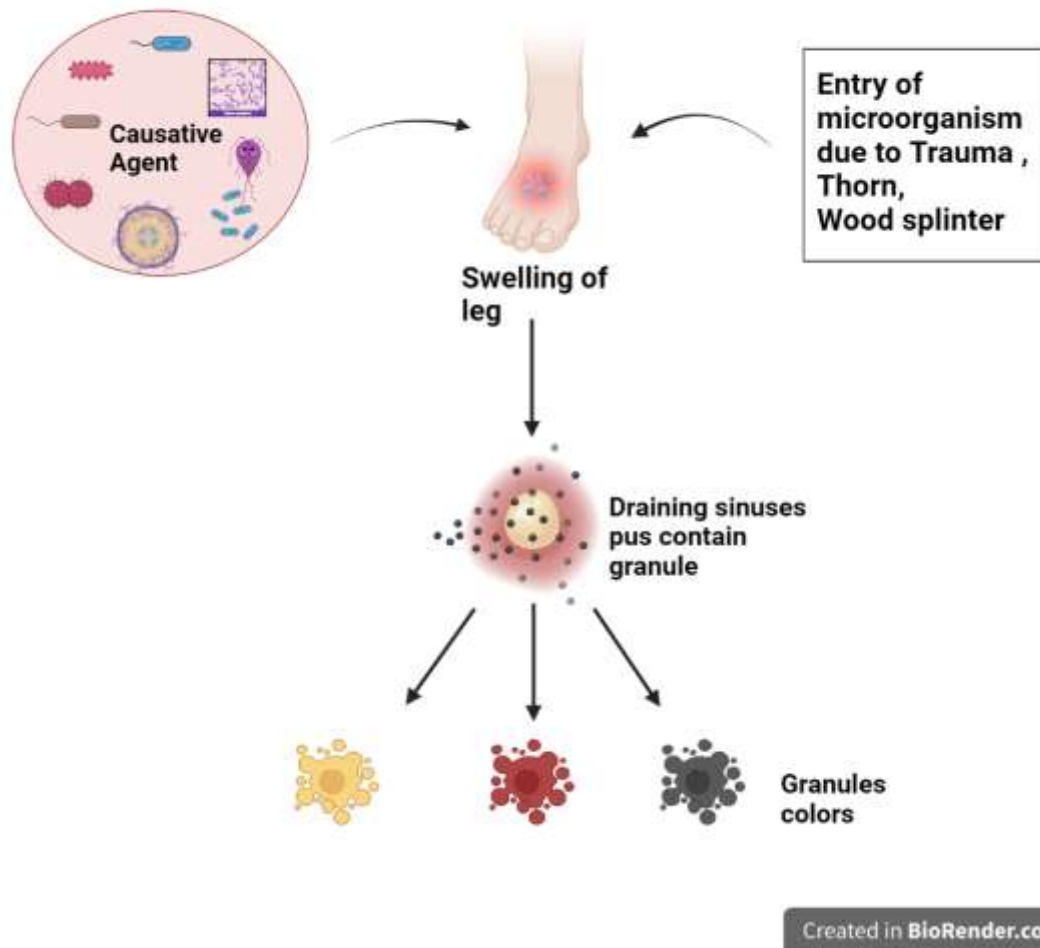
mycetoma are not just seen in the limbs; they can occur across the entire body.

The majority of instances are often seen in the feet (70%), hands (12%), legs, as well as knee joints. In locations where the disease is very prevalent, additional body parts may also be impacted. The arm, head and neck, thighs, and perineum are a few of them. Occasionally, the eyelid, vulva, orbit, scrotum, chest and abdominal walls, facial bones, mandible, para nasal sinuses, and ancient injuries may also be impacted. Locally, through the lymphatic system, or very rarely, into the bloodstream, mycetoma can spread. In particularly severe cases, secondary nodules might develop in the afflicted location along with more distant lymphatic metastases. Actinomycetoma exhibits secondary sites more frequently than eumycetoma, suggesting that bacteria may spread more rapidly. The mycetoma lesion is thought to release chemicals that have an aesthetic effect, thus mycetoma is often painless. When the condition is advanced, the lack of pain may be brought on by endarteritis obliterans or tight fibrous tissue response, or it may be the result of inadequate nerve vascularization. The invasion of the bone or a subsequent bacterial infection may cause discomfort in the disease's later stages (43,45, 46, 47, 48, 49).

PATHOGENESIS

Since mycetoma predominantly affects subcutaneous tissue and the dermis and very rarely causes mild systemic illness, it is classified as a subcutaneous infection(). All subcutaneous mycoses are brought on by bacteria or fungus that penetrate the skin through an injury, frequently a thorn puncture or splinter. Recent case reports lacking a trauma history have cast doubt on this strategy. The disease's incubation time varies and is not clearly understood; some people arrive with symptoms that continue for several weeks while others do so for years. The patient's precise memory of the trauma is frequently unreliable. Furthermore, due to patients' delayed presentation (after visible swelling or drainage), a lack of readily available medical facilities, and patients' dread of amputation, these aspects are difficult to study(50-54).

Mycetoma Pathogenesis



Created in BioRender.com bio

DIAGNOSIS

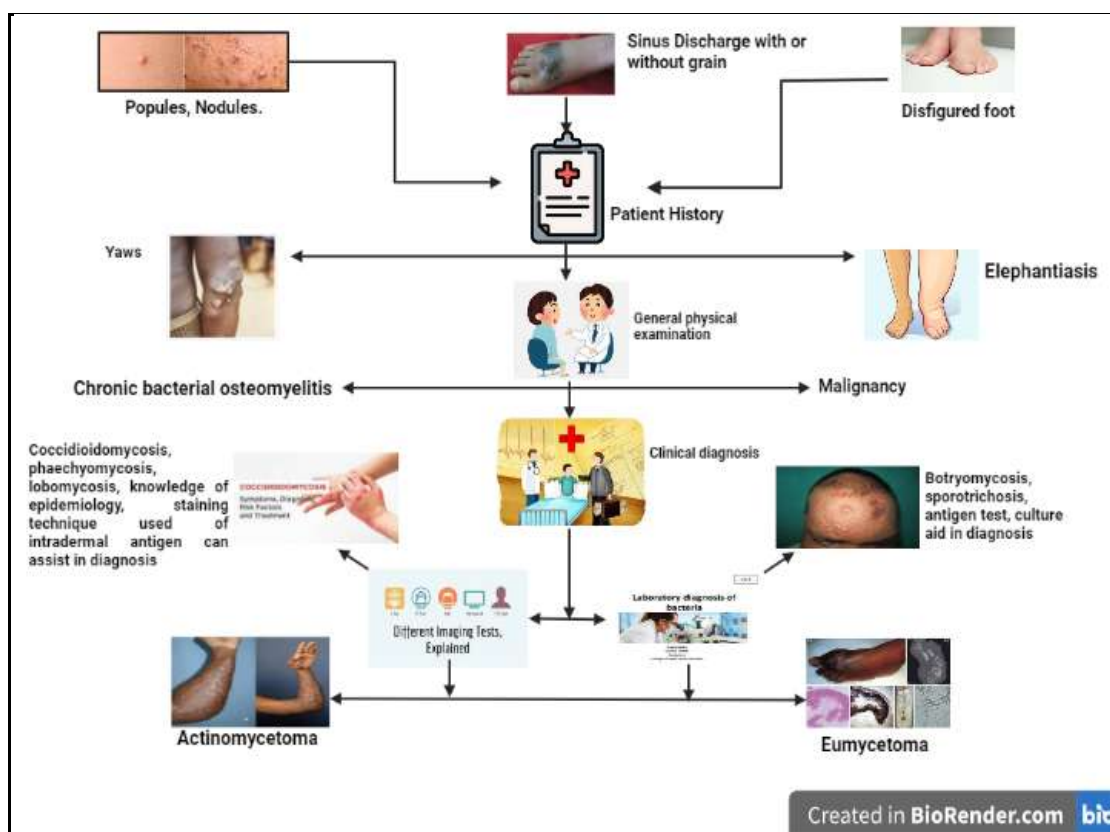
A technique to help a doctor solve a suspected case of mycetoma is provided, along with a thorough discussion of the characteristics of the condition **Fig no.2**. Patients from endemic areas who appear with papules, nodules, induration, edema, or scarred feet need to be closely examined, and their age, sex, and employment need to be taken into consideration about its incidence. Unlike elephantiasis, which causes

Although chronic bacterial osteomyelitis can imitate it, it is typically accompanied by fever and discomfort at the afflicted locations, unlike mycetoma, unless a bacterial infection is also present. Mycetoma is closely related to fungi illnesses such as botryomycosis, sporotrichosis,

periodic, severe pain episodes, these patients seldom ever report of pain(55, 56). Yaws mimics mycetoma, but because it is infectious, close contacts are more likely to get it easily. It often affects children, with 70% of cases occurring before the age of 15, and 70% of cases are infants. The lesions in Yaws are painful and itchy, in contrast to mycetoma. Malignancy must be ruled out when illness progression is rapid, followed by significant weight loss and systemic involvement. blastomycosis, chromoblastomycosis, coccidioidomycosis, phaeohyphomycosis, lobomycosis, and paracoccidioidomycosis. The doctor can make a presumptive diagnosis with the help of knowledge about their epidemiology and clinical course. Focused inquiry at various levels

of the facility also aids the doctor in making the correct diagnosis as indicated by the algorithm Fig no. 2. A medical condition that results in persistently swollen and misshapen feet that are

characterised by draining sinuses should be taken into consideration. Furthermore, several crucial diagnostic instruments, their drawbacks, and the level of the healthcare system(57-61).



MYCOLOGIC/BACTERIOLOGIC DIAGNOSIS

Macroscopic and microscopic features of the grains

The proper diagnosis depends greatly on mycological as well as bacteriological tests. The size, color, and structure of the grains removed vary; upon close inspection, grains are employed for quick but transient identification of the causative agents. Mycetoma's causing factors have been traced to more than 30 species, but because many of these pathogens' grains have similar physical traits, it is still necessary to identify the causative agent using cultures Refer Table no. 2 (62-66). The diameter of the grains differs based on the type of eumycetoma they develop by the *Actinomadura madurae*, *Actinomadura pelletieri*, and members of the genus *Madurella* (particularly *Madurella mycetomatis*). *Actinomycetoma* causes tiny, almost perceptible grains. Color of the greatest prevalent species'

grains. For finding the mycetoma-causing organisms, culture is crucial. To remove impurities, the purulent discharge material must be centrifuged, settled, and washed many times with saline.

To quickly identify the causative agents, colony development should be monitored every day, and questionable colonies should be reproduced in novel medium. Fungal cultures should be preserved for up to six weeks before being dismissed as negative since eumycetoma develop more slowly than actinomycetoma. The most frequent causes of illness identified in Brazil's macroscopic and microscopic characteristics are discussed here:

Nocardia brasiliensis (an aerobic actinomycete) grains are uneven in form, soft in substance, and white to yellow in color. Upon visual inspection, clubs are frequently not visible. At the room temperature and at 37°C, grains are cultivated in media such Sabouraud agar, chocolate

agar, and Czapeck-dox agar. Small white colonies can be seen after the initial week; in rare occasions, colonies are coated with a thin, brief, and white aerial mycelium associated with the breaking up of bacterial filaments. Colonies emit a pungent "wet soil" odor. According to the Kinyoun technique, *N. brasiliensis* exhibits gram-positive, branching bacterial threads that break apart into coccoid and bacillary structures in Gram-stained smears.

On Sabouraud agar, chocolate agar, and Czapeck-dox agar at 25–37°C, *Nocardia* asteroids grows well. The colonies are initially raised, glabrous, ridged, and granular in appearance; their color is often orange, however, it can also be yellow or pink. Branching, fragile, and twisted filaments of 1 mm are seen breaking up into bacillary and coccoid formations on Gram-stained smears. *Actinomadura madurae* has round or oval, white-yellow granules that are insoluble in acetic acid and KOH 20% under close inspection. It develops best at 37 °C and grows at room temperature. Colonies are projecting, circular, and white-yellow at first before becoming pink or red-raw. Cultures are produced in vegetable broth, glycerol-gelatin, and the Lowenstein-Jensen medium.

The grains of *Madurella grisea* are black, oval or irregular in shape, and they are around 1-2 mm long. They develop slowly, but at temperatures between 26 and 30 oC, they can grow to be 17 to 25 mm in diameter in about 30 days. Colonies have a velvety appear, are ridged and cerebriform, and have uneven, rigid edges. Their colour ranges from grey to olive green. The microculture of colonies reveals septate and sterile mycelia with few chlamydo spores and massive moniliform hyphae (3-5 m), approximately 1-3 m in diameter. It thrives in potato and Sabouraud agar.

Black, large grains of *Madurella mycetomatis* range in size from 5mm to more. Initially, colonies have a ridged surface, are yellow or brown in color, and are frequently coated in abrief aerial grey mycelium. On potato agar, cornmeal agar, Sabouraud agar, and Czapeck-dox agar at 370C, colonies thrive. Colonies feature moniliform dematiaceous hyphae and 25-m chlamydo spores. Two months later, 1m-diameter black sclerotia made of polygonal mycelia are seen. It produces two different types of spores: many chlamydo spores as well as simple and branching conidiophores. Lactose but not saccharose was discovered to be assimilable by *Madurella mycetomatis*.

Acremonium kiliense contains broken hyphae and 20 mm white-yellow unevenly formed grains. In Czapeck-dox agar, potato agar, and cornmeal agar at 26 to 30 °C, colony formation is rapid; colonies exhibit a velvety appearance and a white-grey hue. Hyaline, single-celled, and straight conidia are located in the apical section of the conidiophores, having smooth walls, and are held together by a mucilaginous material.

Scedosporium apiospermum possesses hyaline white grains that are 2-4 mm in width and have a variety of shapes. Chlamydo spores and septate hyphae are seen in soft grains. Their colonies thrive in cornmeal agar, potato agar, Sabouraud agar, and Czapeck-dox agar at room temperature as well as at 37 °C. Dark grey colonies contain pyriform aeciospores that are dispersed in the apices of simple or branching conidiophores, as well as single annelloconidia that were generated at the apex of the annellophores. The asexual or anamorphic type of the *Pseudallescheria boydii* species is called *S. apiospermum*(1,13, 67).

Table no. 2 Etiologic agents, macroscopic and microscopic features and culture media for the colonies

Sr no.	Etiological Agent	Macroscopic Culture Characteristics of Medium colonies	Culture Medium	Microscopic Characteristic of Colonies
1.	<i>Nocardia brasiliensis</i>	It is white in color, and the wrinkled on the upper surface, odor is wet soil	Chocolate agar Sabouraud agar Czapeck-dox agar	1 mm fine filaments that break apart to form bacillary structures
2.	<i>Actinomadura madurae</i>	It is a flat-bordered colony that is Glabrous,	Vegetable broth Glycerol-gelatin Lowenstein-Jensen	less than 1 mm in width, branched, lengthy, and twisted fibres. Gram

		serous, and wrinkled.		(+)ve
3.	Acremonium kiliense	short, slow-growing, pink to white aerial mycelium with a violet reverse	Czapeck-dox agar with Sabouraud agar Pork agar Cornmeal gelatin	Simple conidiophore, apical conidia, and hyaline hyphae are grouped together as a circle and held together by mucins.
4.	Scedosporium apiospermum	Quickly growing filaments and cottony, dark-grey mycelium	Sabouraud agar Chocolate agar Czapeck-dox agar	At the tip of annellospores, isolated annelloconidia developed. Pyriform aleuriospores are dispersed in the apices of conidiospores that are simple or branching. Coremia is made up of conidiospore strands.
5.	Madurella grisea	Darkness reverse, ridged surfaces, uneven edges, and shades of grey to olive-green.	Sabouraud agar Potato agar	Dematiaceous septate mycelia with rare chlamydo spores; presence of sclerotia (AB)
6.	Madurella mycetomatis	It is Yellow or brown, ridged surfaces	Sabouraud agar Potato agar Cornmeal agar Czapeck-dox agar	Simple and branching conidiophores, 25 m in diameter moniliform dematiaceous hyphae, and many chlamydo spores.

TREATMENT

A proper diagnosis is necessary for mycetoma therapy. Because the therapies change depending on whether the root cause is bacterial or fungal, it is crucial to specify. Depending on the degree, extent, and location of the infections, antibiotics may be taken alone or in various combinations to treat actinomycetoma. However, we think the optimum treatment response comes from combining antibiotics with surgical operations. Systemic antifungal medications and surgical excision are used for the treatment of eumycetoma.

Lower tissues may be affected by eumycetomas, necessitating extensive surgical excisions and occasionally amputations. Each 150–180 days, stepwise surgical operations are performed in our office to remove the contaminated tissue while continuing the therapeutic therapy. This has prevented 42 incidences of limb amputation in the people we serve. In order to control for recurrent lesions by laboratory and radiographic studies, patient follow-up is ongoing. It occurs every four months over the first two years until a complete clinical and radiological cure is established ((1, 13, 62, 68,).).

In the 1940s and 1950s, sulphonamides and diamino diphenyl sulfone (Dapsone - DDS) were used for treating actinomycetoma effectively, and in a few instances, they were successful in curing the condition. Actinomycetoma was first treated with trimethoprim/sulfamethoxazole (TMP-SMX) in the 1960s. Streptomycin, isoniazid, rifampicin, and minocycline were administered instead in individuals who were resistant to TMP-SMX(1, 69).

Actinomycetoma is now treated with TMP-SMX (40/8mg/kg/day) every 12 hours for a period of five weeks together with amikacin (15mg/kg/day) for three weeks. It is advised to use one to four 5-week cycles. Renal and audiometric monitoring is required prior to, during, and following the cycles.

AS well as TMP-SMX and amikacin should be swapped out in instances that are resistant or in those who have allergies to the drug combination. Instead, amoxicillin-clavulanate and netilmicin should be used instead. Amoxicillin-clavulanate monotherapy is advised during pregnancy. Amikacin is paired with a carbapenem drug, such as imipenem or meropenem, in instances when TMP-SMX is resistant(1).

Since there are few studies focusing on the treatment of eumycetoma, prospective clinical trials are required to assess the therapeutic potential of the available antifungals. The most often prescribed medication for the treatment of eumycetoma is itraconazole. Its bioavailability varies, and digestion is influenced by food consumption and stomach acidity. Current findings show that its extended usage has a positive therapeutic effect, especially when it is followed by surgical excision

The most effective course of therapy, in our opinion, combines itraconazole 200mg/VO every 12 hours for two years with surgical operations every 150–180 days. For 8–10 years, maintenance should be carried out at 200 mg per day with radiological and laboratory controls.

Amphotericin B was the sole systemic antifungal on the market for approximately 30 years. Due to its toxicity and requirement to be supplied parenterally for extended periods of time, it was not commonly utilized for eumycetoma. There is a report of its unsuccessful usage in a case series in Sudan. With dosages ranging from 200 to 400 mg per day for 8 to 24 months of continuous usage, ketoconazole shows a modest therapeutic effect in eumycetomas. Due to its negative effects, ketoconazole is not advised as a first-line therapy, and usage for extended periods of time should be avoided.

Additionally, eumycetomas have been observed to be unresponsive to fluconazole therapy. New medications in the azole class feature minimal toxicity, a broad therapeutic range, and high absorption. They work well for the extended outpatient therapy of mycetoma. There are, however, just a few in vivo and in vitro research. In a small number of patients, voriconazole and posaconazole were evaluated, and the findings were encouraging. Nevertheless, a lengthy course of therapy appears to be necessary despite the positive in vitro activity. Despite having no reports of use in vivo, isavuconazole and fosravuconazole have great in vitro outcomes. Prospective research is required to assess these antifungals.

Exophiala jeanselmei caused eumycetomas, and high dosage terbinafine (1000mg/day) for durations of 24-48 weeks proved effective against them: 25% of patients were cured, while 55% of people significantly improved. Terbinafine, however, proved ineffective against deep infections brought on by *S. apiospermum*(1, 62, 70).

II. CONCLUSION

Since mycetoma is an extremely painless disorder, it is frequently discovered when the affected portion has already undergone permanent deformation. Due to the illness's chronic nature, there is a significant chance that a bacterial infection will develop on top of it, worsening the condition.infection that might make the condition worse. Increased discomfort, weakness, and septicemia, which can be lethal if left untreated, can all result from this. Therefore, a proper mycetoma diagnosis is necessary.

REFERENCES

- [1]. Reis CMS, Reis-Filho EGM. Mycetomas: an epidemiological, etiological, clinical, laboratory and therapeutic review. *An Bras Dermatol.* 2018 Jan-Feb;93(1):8-18. doi: 10.1590/abd1806-4841.20187075. PMID: 29641691; PMCID: PMC5871356.
- [2]. Relhan V, Mahajan K, Agarwal P, Garg VK. Mycetoma: An Update. *Indian J Dermatol.* 2017 Jul-Aug;62(4):332-340. doi: 10.4103/ijd.IJD_476_16. PMID: 28794542; PMCID: PMC5527712.
- [3]. Ahmed, A. O., van Leeuwen, W., Fahal, A., van de Sande, W., Verbrugh, H., & van Belkum, A. (2004). Mycetoma caused by *Madurella mycetomatis*: a neglected infectious burden. *The Lancet. Infectious diseases*, 4(9), 566–574. [https://doi.org/10.1016/S1473-3099\(04\)01131-4](https://doi.org/10.1016/S1473-3099(04)01131-4)
- [4]. van Belkum, Alex & Fahal, Ahmed & Sande, Wendy. (2013). Mycetoma Caused by *Madurella mycetomatis*: A Completely Neglected Medico-social Dilemma. *Advances in experimental medicine and biology.* 764. 179-89. 10.1007/978-1-4614-4726-9_15.
- [5]. Fahal, Ahmed Hassan, Suliman Hussein Suliman, and Roderick Hay. 2018. "Mycetoma: The Spectrum of Clinical Presentation" *Tropical Medicine and Infectious Disease* 3, no. 3: 97. <https://doi.org/10.3390/tropicalmed3030097>
- [6]. Emery, D., Denning, D.W., 2020. The global distribution of actinomycetoma and eumycetoma. *PLOS Neglected Tropical Diseases* 14, e0008397.. <https://doi.org/10.1371/journal.pntd.0008397>

- [7]. P. Verma, A. Jha, Mycetoma: reviewing a neglected disease, *Clinical and Experimental Dermatology*, Volume 44, Issue 2, 1 March 2019, Pages 123–129, <https://doi.org/10.1111/ced.13642>
- [8]. Ahmed AO, Abugroun ES. Unexpected high prevalence of secondary bacterial infection in patients with mycetoma. *J Clin Microbiol.* 1998 Mar;36(3):850-1. doi: 10.1128/JCM.36.3.850-851.1998. PMID: 9508332; PMCID: PMC104645.
- [9]. Karrakchou, B., Boubnane, I., Senouci, K., Hassam, B., 2020. *Madurella mycetomatis* infection of the foot: a case report of a neglected tropical disease in a non-endemic region. *BMC Dermatology* 20.. <https://doi.org/10.1186/s12895-019-0097-1>
- [10]. van de Sande WWJ (2013) Global Burden of Human Mycetoma: A Systematic Review and Meta-analysis. *PLoS Negl Trop Dis* 7(11): e2550. doi:10.1371/journal.pntd.0002550
- [11]. S. A. Ahmed; W. W. J. Van De Sande; M. Desnos-ollivier; A. H. Fahal; N. A. Mhmoud; G. S. De Hoog (2015). Application of Isothermal Amplification Techniques for the Identification of *Madurella mycetomatis*, the Prevalent Agent of Human Mycetoma. , -. doi:10.1128/JCM.01544-15
- [12]. Nenoff P, van de Sande WW, Fahal A H, Reinel D, Schöfer H. Eumycetoma and actinomycetoma - an update on causative agents, epidemiology, pathogenesis, diagnostics and therapy. *J Eur Acad Dermatol Venereol.* 2015;29:1873-83.
- [13]. van de Sande WW, Fahal AH, Goodfellow M, Mahgoub el S, Welsh O, Zijlstra EE. Merits and Pitfalls of Currently Used Diagnostic Tools in Mycetoma. *PLoS Negl Trop Dis.* 2014;8:e2918
- [14]. Ahmed AO, van Leeuwen W, Fahal A, van de Sande WWJ, Verbrugh H, van Belkum A. Mycetomacaused by *Madurella mycetomatis*: a neglected infectious burden. *Lancet Infect Dis* 2004; 4: 566–74
- [15]. Kwon-Chung KJ, Bennet JE. *Medical Mycology*. Philadelphia: Lea and Febiger; 1992
- [16]. Ibrahim AI, El Hassan AM, Fahal A, van de Sande WWJ. A histopathological exploration of the Madur-ella mycetomatis grain. *PLoS One* 2013; 8: e57774.
- [17]. Wendy W.J. van de Sande; Johan de Kat; Jojanneke Coppens; Abdalla O.A. Ahmed; Ahmed Fahal; Henri Verbrugh; Alex van Belkum (2007). Melanin biosynthesis in *Madurella mycetomatis* and its effect on susceptibility to itraconazole and ketoconazole. , 9(9), 1114–1123. doi:10.1016/j.micinf.2007.05.015
- [18]. Ibrahim, A.I., El Hassan, A.M., Fahal, A., Van De Sande, W.W., 2013. A Histopathological Exploration of the *Madurella mycetomatis* Grain. *PLOS ONE* 8, e57774.. <https://doi.org/10.1371/journal.pone.0057774>
- [19]. Elinov NP (1984) Carbohydrates and their role in the biology of pathogenicfungi. *Zentralbl Bakteriol Mikrobiol Hyg A.* 257(2): 246–56.
- [20]. Erb-Downward JR, Huffnagle GB (2006) Role of oxylipins and other lipidmediators in fungal pathogenesis. *Future Microbiol.* 1(2): 219–27.
- [21]. Shea JM, Del Poeta M (2006) Lipid signaling in pathogenic fungi. *Curr OpinMicrobiol.* 9(4): 352–8.
- [22]. Heung LJ, Luberto C, Del Poeta M (2006) Role of sphingolipids in microbial pathogenesis. *Infect Immun.* 74(1): 28–39
- [23]. Ibrahim AI, El Hassan AM, Fahal A, van de Sande WWJ. A histopathological exploration of the Madur-ella mycetomatis grain. *PLoS One* 2013; 8: e57774. doi:10.1371/journal.pone.0057774PMID:23483927
- [24]. Findlay GH, Vismer HF. Black grain mycetoma. Atomic absorption and spark source mass spectrophotometry of the tissue grain in *Madurella mycetomi* infection. *Br J Dermatol* 1977; 97: 497–9. PMID:588463
- [25]. van de Sande WW, de Kat J, Coppens J, Ahmed AO, Fahal A, Verbrugh H, van Belkum A. Melanin bio-synthesis in *Madurella mycetomatis* and its effect on susceptibility to itraconazole and ketoconazole. *Microbes Infect* 2007; 9: 1114–23.
- [26]. Relhan V, Mahajan K, Agarwal P, Garg VK. Mycetoma: An Update. *Indian J Dermatol.* 2017 Jul-Aug;62(4):332-340.

- doi: 10.4103/ijd.IJD_476_16. PMID: 28794542; PMCID: PMC5527712.
- [27]. Kwon-Chung KJ, Bennett JE. Mycetoma. In: Medical Mycology. Philadelphia: Lea & Febiger; 1992. p. 560-93. Back to cited text no. 3
- [28]. Carter HV. On a New and Striking form of Fungus Disease Principally Affecting the Foot and Prevailing Endemically in Many Parts of India. Transactions of the Medical and Physical Society of Bombay 1860;6:104-42. Back to cited text no. 4
- [29]. Pinoy E. Actinomycoses and mycetomas. Bull Inst Pasteur 1913;11:929. Back to cited text no. 5
- [30]. Chalmers AJ, Archibald RG. A Sudanese maduromycoses. Ann Trop Med 1916;10:169. Back to cited text no. 6
- [31]. Hay RJ, Mackenzie DW. Mycetoma (madura foot) in the United Kingdom – A survey of forty-four cases. Clin Exp Dermatol 1983;8:553-62. Back to cited text no. 9
- [32]. Chaudhuri BN, Maiti PK, Sil J. Antibiotic sensitivity patterns of actinomycetes isolated from patients of actinomycetoma. Indian J Med Res 1997;105:162-6.
- [33]. Fahal AH, Sabaa AH. Mycetoma in children in Sudan. Trans R Soc Trop Med Hyg 2010;104:117-21. Back to cited text no. 13.
- [34]. Zarei Mahmoudabadi A, Zarrin M. Mycetomas in Iran:a review article. Mycopathologia 2008;165:135-41. Back to cited text no. 14.
- [35]. López Martínez R, Méndez Tovar LJ, Lavallo P, Welsh O, Saúl A, Macotela Ruíz E. Epidemiology of mycetoma in Mexico: Study of 2105 cases. Gac Med Mex 1992; 128:477- 81.
- [36]. Van De Sande W., Taha, H., Fahal, A., 2015. Mycetoma: epidemiology, treatment challenges, and progress. Research and Reports in Tropical Medicine 31.. <https://doi.org/10.2147/rrtm.s53115>
- [37]. Bonifaz A, Tirado-Sánchez A, Calderón L, Saúl A, Araiza J, Hernández M, González GM, Ponce RM. Mycetoma: Experience of 482 Cases in a Single Center in Mexico. PLoS Negl Trop Dis. 2014;8:e3102.
- [38]. Van de Sande WW. Global Burden of Human Mycetoma: A Systematic Review and Meta-analysis. PLoS Negl Trop Dis. 2013;7: e2550
- [39]. Mattioni S, Develoux M, Brun S, Martin A, Jaureguy F, Naggara N, Bouchaud O. Management of mycetomas in France. Med Mal Infect. 2013;43:286-94.
- [40]. Tomczyk S, Deribe K, Brooker SJ, Clark H, Rafique K, Knopp S, Utzinger J, et al. Association of Footwear Use and Neglected Tropical Diseases: A Systematic Review and Meta-Analysis. PLoS Negl Trop Dis. 2014;8:e3285.
- [41]. Relhan V, Mahajan K, Agarwal P, Garg VK. Mycetoma: An Update. Indian J Dermatol. 2017 Jul-Aug;62(4):332-340. doi: 10.4103/ijd.IJD_476_16. PMID: 28794542; PMCID: PMC5527712.
- [42]. Rippon JW. Medical mycology, the pathogenic fungi and the pathogenic actinomycetes, 3rd edn. Philadelphia: WB Saunders Company, 1988
- [43]. Boiron P, Locci R, Goodfellow M, et al. Nocardia, nocardiosis and mycetoma. Med Mycol 1998; 36: 26–37.
- [44]. McGinnis MR. Mycetoma. Dermatol Clin 1996; 14: 97–104
- [45]. Gumaa SA. The etiology and epidemiology of mycetoma. Sudan Med J 1994; 32: 14–22.
- [46]. Fahal AH, Suliman SH. Clinical presentation of mycetoma. Sudan Med. J 1994; 32: 46–66
- [47]. Fahal AH, el Hassan AM, Ahmed AOA, Sheik HE. Cystic mycetoma: an unusual clinical presentation of Madurella mycetomatis infection. Trans R Soc Trop Med Hyg 1998; 92: 66–67.
- [48]. Ahmed AO, Abugroun ES, Fahal A, Zijlstra E, van Belkum A, Verbrugh HA. Unexpected high prevalence of secondary bacterial infection in patients with mycetoma. J Clin Microbiol 1998; 36: 850–51.
- [49]. Fahal AH. Mycetoma updates. Mycetoma Research Center, University of Khartoum, Sudan. <http://www.mycetoma.org> (accessed Aug 9, 2004).
- [50]. Hay RJ. Deep fungal infections. In: Freedberg IM, Eisen AZ, Wolff K, et al., editors. Fitzpatrick's dermatology in general medicine. 5th edition. Vol. 2. New York: McGraw-Hill; 1999: 2372-7.

- [51]. Pang KR, Wu JJ, Huang DB. Subcutaneous fungal infections. *Dermatol Ther* 2004;17 (6): 523-31.
- [52]. Maiti PK, Ray A, Bandyopadhyay S. Epidemiological aspects of mycetoma from a retrospective study of 264 cases in West Bengal. *Trop Med Int Health* 2002 Sep; 7 (9): 788-92
- [53]. Foltz KD, Fallat LM. Madura foot: atypical finding and case presentation. *J Foot Ankle Surg* 2004 Sep-Oct; 43 (5): 327-31.
- [54]. Maiti PK, Ray A, Bandyopadhyay S. Epidemiological aspects of mycetoma from a retrospective study of 264 cases in West Bengal. *Trop Med Int Health* 2002 Sep; 7 (9): 788-92.
- [55]. Nazzaro G, Veraldi S. Mycetomas: the experience of the dermatology unit of the University of Milan. *Dermatopathology (Basel, Switzerland)*.2018;5(1):6–9. <https://doi.org/10.1159/000486236> (Epub 2018/05/03).
- [56]. Akogun OB, Akogun MK, Apake E, Kale OO. Rapid community identification, pain and distress associated with lymphoedema and adenolymphangitis due to lymphatic filariasis in resource-limited communities of North-eastern Nigeria. *Acta Tropica*. 2011;120(Suppl 1):S62–8. <https://doi.org/10.1016/j.actatropica.2011.03.008> (Epub 2011/04/08).
- [57]. Book AU, Awah PK, Mou F, Nichter M. Yaws resurgence in Bankim, Cameroon: the relative effectiveness of different means of detection in rural communities. *PLoS Negl Trop Dis*. 2017;11(5):e0005557. <https://doi.org/10.1371/journal.pntd.000557> (Epub 2017/05/10).
- [58]. Mattox TW. Cancer cachexia: cause, diagnosis, and treatment. *Nutr Clinical Practice*. 2017;32(5):599–606. <https://doi.org/10.1177/0884533617722986> (Epub 2017/08/22).
- [59]. Calhoun JH, Manring MM. Adult osteomyelitis. *Infect Dis Clin North Am*. 2005;19(4):765–86. <https://doi.org/10.1016/j.idc.2005.07.009> (Epub 2005/11/22).
- [60]. Stone B, Street M, Leigh W, Crawford H. Pediatric tibial osteomyelitis. *JPediatr Orthop*.2016;36(5):534–40. <https://doi.org/10.1097/bpo.00000000000000472> (Epub 2016/06/09).
- [61]. Rivitti EA, Aoki V. Deep fungal infections in tropical countries. *Clin Dermatology*. 1999;17(2):171–90 (Epub 1999/05/20).
- [62]. Nenoff P, van de Sande WW, Fahal AH, Reinel D, Schöfer H. Eumycetoma and actinomycetoma - an update on causative agents, epidemiology, pathogenesis, diagnostics and therapy. *J Eur Acad Dermatol Venereol*. 2015;29:1873–1883.
- [63]. Mattioni S, Develoux M, Brun S, Martin A, Jaureguy F, Naggara N, Bouchaud O. Management of mycetomas in France. *Med Mal Infect*. 2013;43:286–294
- [64]. Yousif BM, Fahal AH, Shakir MY. A new technique for the diagnosis of mycetoma using fixed blocks of aspirated material. *Trans R Soc Trop Med Hyg*. 2010;104:6–9
- [65]. López-Martínez R, Méndez-Tovar LJ, Bonifaz A, Arenas R, Mayorga J, Welsh O, et al. Update on the epidemiology of mycetoma in Mexico. A review of 3933 cases. *Gac Med Mex*. 2013; 149:586–592.
- [66]. Lacaz CS, Porto E, Martins JEC, Heins-Vaccari EM, Takahashi de Melo N. *Tratado de Micologia Médica*. Sarvier: São Paulo; 2002
- [67]. ein HA, Fahal AH, Mahgoub el S, El Hassan TA, Abdel-Rahman ME. Predictors of cure, amputation and follow-up dropout among patients with mycetoma seen at the Mycetoma Research Centre, University of Khartoum, Sudan. *Trans R Soc Trop Med Hyg*. 2012;106:639–644.
- [68]. Zijlstra EE, van de Sande WWJ, Welsh O, Mahgoub ES, Goodfellow M, Fahal AH. Mycetoma: a unique neglected tropical disease. *Lancet Infect Dis*. 2016;16:100–112
- [69]. Mencarini J, Antonelli A, Scoccianti G, Bartolini L, Roselli G, Capanna R, et al. Madura foot in Europe: diagnosis of an autochthonous case by molecular approach and review of the literature. *New Microbiol*. 2016;39:156–15
- [70]. Welsh O, Al-Abdely HM, Salinas-Carmona MC, Fahal AH. Mycetoma Medical Therapy. *PLoS Negl Trop Dis*. 2014;8:e3218